



## PATIENT PRESENTING CLINICAL SIGNS

Zelda Paz Vivas Fell off bed and injured mouth

## SPECIES

Canine

## RADIOGRAPHIC STUDY OF THE HEAD

A single intraoral radiograph of one mandibular body in JPEG format available for review.

## RADIOGRAPHIC FINDINGS

## BREED

Shih Tzu

The radiograph demonstrates a segment of the mandible containing one lower carnassial tooth (09).

## SEX

FS

The mandibular bone appears thinned in general consistent with horizontal alveolar bone atrophy.

The tooth 09 shows mild widening of the periodontal ligament space, suggestive of periodontitis.

Tooth 08 is absent and tooth 07 presents severe periodontitis with tooth loosening.

## AGE

10yr

## RADIOGRAPHIC DIAGNOSIS

- Complete non-displaced transverse fracture of the mandibular body at the level of the carnassial tooth
- Alveolar bone atrophy in the fractured segment
- Periodontal disease: mild periodontitis tooth 09, severe periodontitis with mobility of tooth 07, tooth 08 absent.

## INTERPRETED BY

Nele Eley (Ondreka),  
DVM Dr. med. vet.,  
DipECVDI

## INTERPRETATION OF FINDINGS & FURTHER RECOMMENDATIONS

## HOSPITAL NAME

Chappelle Veterinary  
Clinic

Bone atrophy may have contributed to loosening of biomechanical strength of the bone and development of a fracture with minor trauma. A complete fracture of the affected mandibular segment is identified and referral to a veterinary dental or surgical specialist for fracture management is recommended. If not performed already, dental evaluation and possible extraction or treatment of the 07 and 09 is recommended as well. Consider follow-up radiographs to monitor fracture healing and osseous integrity.

## REFERRING VET

Bassam Abdelmalek

## INVOICE

22945

## DATE

11/12/2025



## PATIENT

Zelda Paz Vivas

## SPECIES

Canine

## BREED

Shih Tzu

## SEX

FS

## AGE

10yr

## INTERPRETED BY

Nele Eley (Ondreka),  
DVM Dr. med. vet.,  
DipECVDI

## HOSPITAL NAME

Chappelle Veterinary  
Clinic

## REFERRING VET

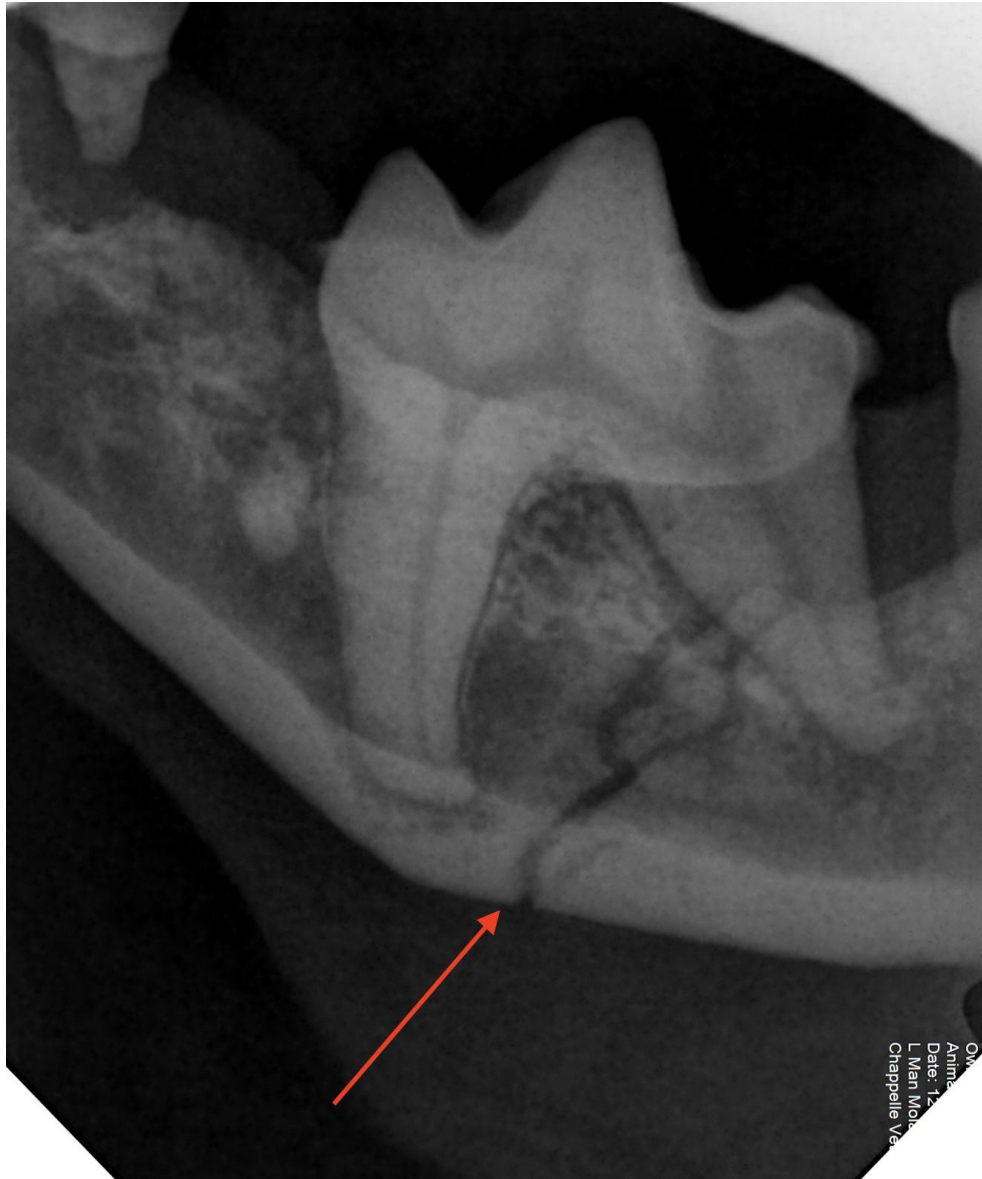
Bassam Abdelmalek

## INVOICE

22945

## DATE

11/12/2025



The information and recommendations provided are based on the images presented by the referring veterinarian. No evaluation can be communicated regarding pathology that was not visible in the image/video clips provided.

Thank you for this referral. If the clinical or image interpretation does not parallel your findings or if I can be of any further assistance please contact me.

Nele Eley (Ondreka), DVM, Dr. med. vet., DipECVDI



## PATIENT

Zelda Paz Vivas

European Specialist in Veterinary Diagnostic Imaging, Cert. Radiology,  
Senior lecturer University of Giessen/Germany, Veterinary Faculty, Department of Radiology.  
[info@sonopath.com](mailto:info@sonopath.com)

## SPECIES

Canine

## BREED

Shih Tzu

## SEX

FS

## AGE

10yr

## INTERPRETED BY

Nele Eley (Ondreka),  
DVM Dr. med. vet.,  
DipECVDI

## HOSPITAL NAME

Chappelle Veterinary  
Clinic

## REFERRING VET

Bassam Abdelmalek

## INVOICE

22945

## DATE

11/12/2025